55th ANNUAL DIAGNOSTIC SLIDE SESSION 2014

CASE 2014-1

Submitted by Vanessa D. Smith, Dianne Wilson, Janna Neltner, Peter Nelson and Craig Horbinski

Department of Pathology, University of Kentucky Chandler Medical Center, Lexington KY 40536

Clinical History:
The patient was a 72-year-old woman hospitalized for management of pleural and pericardial effusions and shock complicating chronic rheumatoid arthritis. As the patient was encephalopathic on admission, neurologic evaluation was limited. Per her family and primary care provider, the patient had a history of depression and possible wide-based gait, but no other overt neurological symptoms. She was employed as a substitute teacher and living independently. MRI of the head without gadolinium contrast was obtained, showing generalized cerebral and cerebellar atrophy, in addition to susceptibility-weighted imaging signal loss involving the bilateral substantia nigra and striatum, suggesting increased iron (radiographic image provided). She expired ten days after admission following withdrawal of life support.

Autopsy Findings:
Gross CNS findings were significant for well-delineated prominent blue coloration of the bilateral caudate nucleus, putamen and globus pallidus (gross image enclosed). The gross exam was otherwise unremarkable.

Materials Submitted: 1 H&E stained slide of the basal ganglia, serial MRI imaging and post-mortem gross photograph

Points for Discussion: 1. Additional stains
2. Differential diagnosis
3. Disease characteristics

55th ANNUAL DIAGNOSTIC SLIDE SESSION 2014.

CASE 2014-02

Submitted by:

Joseph M Fullmer MD, PhD
Upstate Medical University
Neuropathology and Surgical Pathology
750 East Adams Street, UH-6804B
Syracuse, NY 13210

Clinical History:

The patient is a 74 yo woman with a skull based tumor. She underwent resection of what was reported to be a pituitary adenoma, evaluated at an outside hospital 16 years ago in 1997, underwent radiation therapy and had reportedly done well in the interim while receiving intermittent follow up. However, several months before presentation (early 2013), she had mild bitemporal hemianopsia, slowly progressing right cheek numbness, chronic rhinosinusitis, and deviated nasal septum. Examination of CT scan revealed a 4.3 cm mass centered in the sphenoid sinus eroding right sphenoid bone, invading and extending beyond the sella, infiltrating muscle and the right carotid canal wall. Due to having a pacemaker, the patient was unable to undergo MRI which limited evaluation to some degree. The lesion was in the previous radiation field and beyond. Radiographically it was uncertain if the current lesion was a recurrence, related to any previous treatment (i.e. radiation induced), or something entirely new.

The mass was biopsied. H&E sections revealed the mass as shown. Many stains were performed and the lesion was positive for Vimentin, variably positive for S-100 and negative for HMB-45, MART-1, PAX-8, neurofilament, chromogranin, synaptophysin, and GFAP. Other stains were performed and will be reported at the DSS. She underwent a partial resection (tumor near the carotid could not be resected and tumor was adherent to some of the bones in the sinuses) where the majority of tumor was resected. The immunophenotype of the resected material was identical to that seen in the biopsy. The patient is receiving radiation therapy and follow up imaging. Slides from the 1997 lesion reported to be a pituitary adenoma were also obtained and will be discussed at the DSS.

Material submitted:

H&E stained slide of resected lesion

Points for discussion:

1. Diagnosis
2. Obtaining previous material, when possible
3. Appropriate workup of pituitary adenomas

55th ANNUAL DIAGNOSTIC SLIDE SESSION 2014.

CASE 2014-3

Submitted by: Pallavi P. Gopal, MD, PhD and Edward B. Lee, MD, PhD
Division of Neuropathology, Department of Pathology and Laboratory Medicine
University of Pennsylvania, Philadelphia, PA 19104

Clinical History: The patient is a 57 year old male with history of non-small cell lung cancer status post pneumonectomy and whole brain radiation therapy for brain metastases eight years prior to presentation. He was in his usual state of health until two days prior to admission, when he complained of headache for which he took imitrex and excedrin, and went to sleep. However, he did not wake up the next day and apparently had an episode of bladder incontinence. The patient was taken to the ED by his family, where he had altered mental status and fever (102.4 deg). On neurologic exam, he was able to follow commands, but had a left facial droop, left hemiplegia, and left sided neglect with right gaze preference. A stroke evaluation was negative. A head CT showed an old lacunar infarct but no acute hemorrhage. An MRI showed cortical FLAIR signal in the right frontoparietal region. An EEG revealed right centrotemporal slowing and decreased background activity on the right. Cerebrospinal fluid analysis revealed elevated protein at 74 mg/dl, normal glucose at 50 mg/dl, 0 WBC/microliter, and 0 RBC/microliter. CSF cultures and PCR for VZV and JC virus were negative. A comprehensive workup for CSF and serum paraneoplastic autoantibodies was negative. A repeat MRI performed one week after initial presentation was notable for diffuse gyral thickening in the right hemisphere (increased from prior study) and progressive diffuse meningeal enhancement.

Material submitted:
1. Image of brain MRI: Axial T1 post contrast and axial Flair T2
2. H&E section of “Right frontal lesion" (Virtual Slide)

Points for discussion:
1. Additional stains?
2. Differential diagnosis
3. Pathogenesis

55th ANNUAL DIAGNOSTIC SLIDE SESSION 2014.

CASE 2014 [4]

Submitted by: Leonidas Arvanitis M.D. [1] and Geoffrey Murdoch M.D. [1] Division of Neuropathology, Department of Pathology, University of Pittsburgh Medical Center, 200 Lothrop Street, South Tower, Room M8715, Pittsburgh, PA 15213

Clinical History: The patient is a 39 year-old female who presented to UPMC after having a witnessed seizure while shopping. Her past medical history was significant only for a biopsy proven benign thyroid nodule. She's newly married and has a remote history of tobacco use. She was transferred to the emergency room where an MRI was performed and showed a 1.7 cm mass along the floor of the left middle cranial fossa with adjacent mild vasogenic edema in the elevated overlying left temporal lobe. The patient underwent a left temporal craniotomy with subsequent excision.

Material submitted: MRI images (T1+contrast and FLAIR), Scanned H&E section

Points for discussion: 1. Diagnosis
2. Differential Diagnosis
3. Outcome

55th ANNUAL DIAGNOSTIC SLIDE SESSION 2014

CASE 2014-5

Submitted by: Esther N. Bit-Ivan[1], Jason Wang[2], Jason Park[2], Korgun Koral[2], Charles Timmons[2], and Veena Rajaram[2]

1. Northwestern University/Feinberg School of Medicine, Chicago, IL
2. Children's Medical Center, Dallas, TX

Clinical History:

The patient is a 5 year old female with a history of macrocephaly, developmental delay, seizure disorder, and cerebellar ectopia. She underwent neuroimaging in the form of CT or MRI periodically, the last of which was a head CT obtained 20 months prior to presentation and was normal. She presented to the emergency room with bilateral lower extremity weakness lasting about two hours with concomitant headache, and one episode of emesis. Two weeks prior to presentation, she had had a viral upper respiratory infection. There was no history of trauma. The emergent head CT and subsequent brain MRI showed an intensely enhancing mass (measuring 5.1 cm x 3.1 cm x 3.1 cm) in the right parasagittal frontal lobe. The mass was associated with extensive vasogenic edema of the right frontal lobe and leftward shift of the midline structures. Excision of the lesion was attempted where the tumor "seemed to blend into the brain".

Material submitted: MRI images at initial presentation and H&E stained slide of the mass

Points for discussion: 1. Diagnosis and differential diagnosis
2. Immunohistochemical and genetic findings

55th ANNUAL DIAGNOSTIC SLIDE SESSION 2014.

CASE 2014 [6]

Submitted by:
Matthew D. Cykowski, MD, Suzanne Z. Powell, MD, and J. Clay Goodman, MD
Department of Pathology and Genomic Medicine, Houston Methodist Hospital, and Department of Pathology and Immunology, Baylor College of Medicine
6565 Fannin Street, Suite M227, Houston, Texas 77030

Clinical History:

A 49-year-old right-handed woman originally from Honduras was admitted with a 3-week history of progressive altered mental status, headache, and right-sided weakness. On the day of symptom onset, she presented to an outside hospital and MRI of the brain revealed two ring-enhancing lesions associated with edema (**Figure 1**). She was also diagnosed with AIDS (CD4 count of 38 cells/μL and an HIV viral load of 375,000 copies/mL). The patient underwent an MRI-guided biopsy of the left parietal lesion at the outside hospital. The patient was hospitalized for two additional weeks and eventually was discharged on sulfadiazine and pyrimethamine based on the biopsy diagnosis.

FIG 1

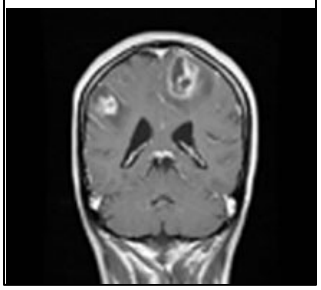

On admission to Ben Taub General hospital, she was afebrile and physical examination was notable for altered mental status and weakness of the right upper and lower extremities (Medical Research Council (MRC) grade of 3/5). There was no sensory deficit. MRI of the brain showed worsening ring-enhancing lesions within the right superior frontal gyrus (1.4 x 1.2 cm) and left parietal lobe (2.4 x 2.2 cm), moderate vasogenic edema and regional mass effect, and adjacent leptomeningeal enhancement. She was started on oral sulfadiazine, pyremethamine, and glucocorticosteroids. On hospital day 5, the patient had worsening mental status and a CT of the head showed enlargement of the right frontal lesion with increased edema.

The brain biopsy slides were obtained from the outside hospital.

The patient was treated with the appropriate therapy and HAART and she survived but remains severely impaired.

Material submitted:

1. Virtual H&E stained glass slide from a biopsy of left parietal mass.
2. Coronal MRI of the brain.

Points for discussion:

1. What are the important epidemiologic factors underlying this disease and how are these relevant to the practice of neuropathology in the United States?
2. What are the neurologic sequelae that may arise from this disease?

55th ANNUAL DIAGNOSTIC SLIDE SESSION 2014

CASE 2014 – 7

Submitted by: Sanda Alexandrescu, M.D.[1], Clinton Turner M.D.[2], and Arie Perry, M.D.[1], Department of Pathology, University of California San Francisco, San Francisco, CA 94143[1], Department of Anatomical Pathology, Auckland City Hospital, New Zealand[2]

Clinical history: 7-year-old girl with a medical history of headaches of two years duration. The past medical history was otherwise unremarkable. Magnetic resonance imaging (MRI) of the brain with and without contrast showed a relatively discrete mass in the tectal area, blocking the aqueduct of Sylvius and causing hydrocephalus (Fig.1). The mass demonstrated focal contrast-enhancement (Fig. 2). A biopsy was submitted for evaluation.

Material submitted:

1) Brain MR images (sagittal T2, sagittal T1+contrast)
2) One hematoxylin-eosin-stained virtual slide

Points for discussion:

1) Differential diagnosis
2) Ancillary studies
3) Prognostic implications

55th ANNUAL DIAGNOSTIC SLIDE SESSION 2014

CASE 2014 [8]

Submitted by: Julia Keith MD, FRCPC
Department of Anatomical Pathology, Sunnybrook Health Sciences Centre
University of Toronto
2075 Bayview Avenue, room E403
Toronto, Ontario, Canada
M4N 3M5
(416)480-6100 x 88055

Clinical History: A previously well 18-year-old man presented with a 2 month history of headache, progressive clumsiness and difficulty walking. Neurological examination documented nystagmus, dysarthria, and ataxia. MRI of the brain revealed multiple T2 hyperintense lesions throughout both cerebellar hemispheres and the cerebellar folia enhanced following gadolinium administration with a leptomeningeal pattern. CSF analysis revealed cellular pleocytosis (69 WBC/hpf (lymphocytic predominance) with mild elevation of protein (0.468 g/L). CSF microbiological studies, flow cytometry and cytology were negative. CT chest, abdomen and pelvis, and testicular ultrasound were normal. Over the ensuing 3 days the patient's cognitive status deteriorated and repeat MRI showed worsening of the cerebellar lesions. Given the non-diagnostic investigations and worsening clinical condition, biopsy of the left cerebellum was undertaken to investigate for potentially treatable conditions including lymphoma.

Material submitted: H&E section of left cerebellar biopsy

Points for discussion: 1. Diagnosis
2. Pathogenesis

55th ANNUAL DIAGNOSTIC SLIDE SESSION 2014.

CASE 2014 – 9

Submitted by: Jesse Lee Kresak, MD, Marie Rivera-Zengotita, MD, Ahmed Alkhasawneh, MD, Samer Al-Quran, MD, Anthony T. Yachnis, MD

University of Florida College of Medicine, 1600 SW Archer Rd, PO Box 100275, Gainesville, FL, 32610

Clinical History:
A 64-year-old female presented with constant right-sided frontal headache that radiated to her cheek and jaw for one month. The patient had a past medical history of cervical cancer, myelofibrosis secondary to polycythemia vera, splenomegaly, and GERD. She had been receiving blood transfusions approximately every 3 weeks and had been hospitalized 3 weeks prior for urosepsis secondary to nephrolithiasis.

An MRI study on admission revealed 2 extra-axial posterior fossa lesions along the inferior cerebellar surfaces that showed variable post-contrast enhancement (left and center image). The left lesion measured 2.5 x 1.2 cm and showed evidence of perilesional edema by T2 (right image) and FLAIR images. The right lesion measured 1.1 x .05 cm. Susceptibility weighted images suggested hemosiderin deposition.

A surgical procedure was performed, which yielded the tissue submitted for study.

Material submitted:
MRI of brain and H&E stained section of left cerebellar lesion

Points for discussion:
1. Diagnosis
2. Etiology

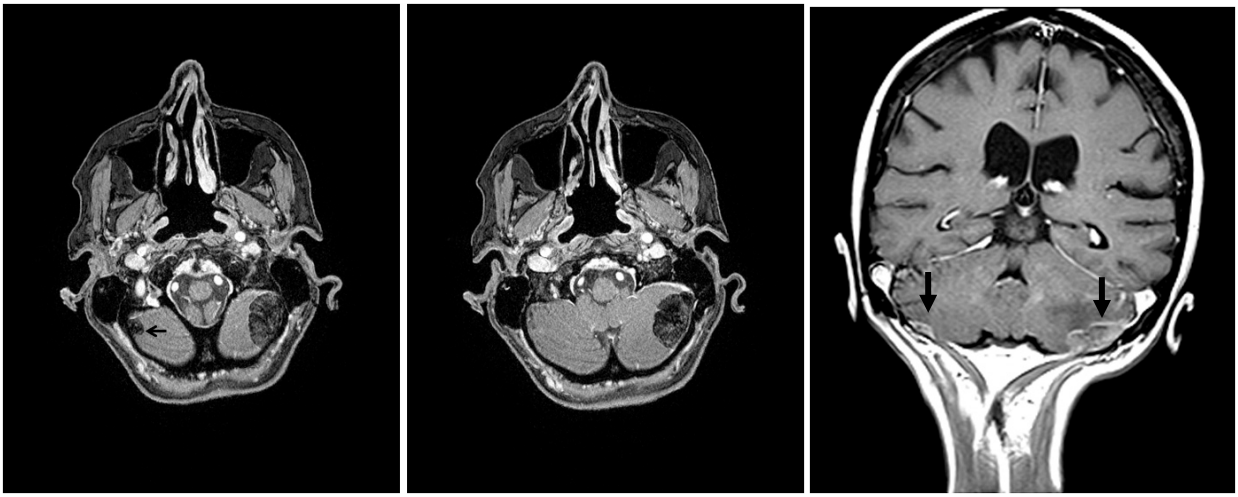

55th ANNUAL DIAGNOSTIC SLIDE SESSION 2014.

CASE 2014-10

Submitted by: Jane Cryan MD, Rebecca Gillani MD PhD, Rebecca Folkerth MD.
Brigham and Women's Hospital, Harvard Medical School, Boston MA

Clinical History:
A 76 year old man with hypertension and hyperlipidemia presented with 1 week of painful right T7 dermatomal rash and paresthesia in the bilateral lower extremities. Physical exam noted right T7 vesicular/erythematous rash, full strength throughout with the exception of mild hip flexor weakness. Reflexes were absent at the knee and trace at the ankles. He walked with an ataxic gait, had diminished pain, light touch and proprioception to the knees. He was treated with Solumedrol and Acyclovir IV. Thoracic spine MRI was limited by patient discomfort. Within several hours, he had speech difficulty, and right arm and bilateral leg weakness. Exam revealed intact cranial nerves, upper limb strength but 0/5 hip flexor strength bilaterally.
The following day, he developed dysphagia and had increased work of breathing. He now had 0/5 strength throughout the upper and lower extremities with the exception of 4/5 strength in the hands and ankles. Reflexes were absent.
CSF glucose 62, total protein 191.5, RBC 11857, WBC 130 (80% Neut, 16% Lymph); Serum varicella zoster virus PCR was positive; CSF positive IgG to VZV.
He was intubated after which he was awake following commands. Eyes were open with full extraocular movements. He had profound proximal greater than distal weakness in all extremities. His exam deteriorated and by day 6 he was ophthalmoplegic and quadriparetic. His blood pressure was labile on pressors. Spine MRI showed questionable cauda equina enhancement. Brain MRI revealed enhancement of cranial nerves III and the right VI/VIII nerves. EMG/NCS revealed severe motor and sensory axonal polyneuropathy with demyelinating features. On day 17, repeat brain MRI was abnormal (see image). After family discussion, he was made comfortable and extubated. An autopsy was performed.

Autopsy findings:
Zoster-like skin ulcers, no evidence of ongoing/active VZV skin infection (no viral cytopathic changes; negative VZV immunostain)
Hepatosplenomegaly
Pulmonary edema

Material submitted:
H&E section(2) right frontal lobe and cauda equine; MRI brain T1W post contrast, Coronal section at genu of CC.

Points for discussion:
Is there a unifying diagnosis?

55th ANNUAL DIAGNOSTIC SLIDE SESSION 2014.

CASE 2014 11

Submitted by:
Inma Cobos, M.D, PhD. and E Tessa Hedley-Whyte, M.D.
C S Kubik Laboratory of Neuropathology
Department of Pathology, Harvard Medical School
Massachusetts General Hospital, WRN 325
55 Fruit Street,
Boston, MA 02114

Clinical History:
A 64 year-old woman with past medical history of metastatic melanoma presented with progressively worsening headaches primarily in the left portion of her neck, extending into the suboccipital area and the area behind her left ear, developing over several months. An MRI of the brain performed to evaluate for metastatic disease showed a 7 x 3 mm homogeneously enhancing mass on the left side of the spinal cord at the C1-C2 area along the intradural course of the vertebral artery. A repeat MRI performed 5 weeks later showed that the mass was now 1 x 1 cm. An angiogram was negative for vascular malformation. A gross total resection of an intradural, extramedullary vascular-appearing tumor on the left side of the spinal cord at the level of the C1 root was performed.

Gross findings:
1 x 1 x 0.6 cm, well-circumscribed, shiny, firm mass with a fleshy, red, rubbery cut surface.

Material submitted:
Gross photograph and H & E (virtual) cross-section of the mass.

Points for discussion: 1. Diagnosis
2. Prognosis