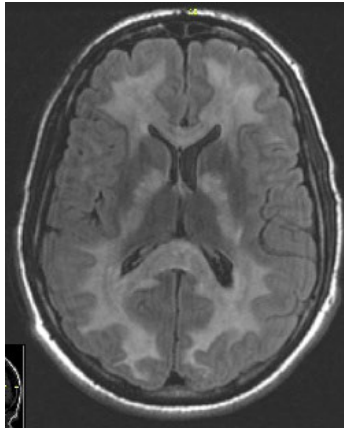


CASE 2012-3

SUBMITTED BY: Joshua Menke, Mark Jentoft, Caterina Giannini, Mayo Clinic, Rochester, MN

CLINICAL HISTORY:

A 24 year-old gentleman with a history of polysubstance abuse was found unresponsive at a New Year's party. He reportedly had taken several drugs, including liquid methadone, lorazepam, and cocaine. CPR was initiated and the patient was intubated and transported to the hospital where he was found to be acidotic with severe rhabdomyolysis. A head CT at the time of admission did not demonstrate any abnormality. The patient stabilized hemodynamically over the next 72 hours and was weaned from norepinephrine and dobutamine. He continued to be unresponsive and would only withdraw to pain. All reflexes remained intact. A MRI on day 4 showed significant and diffuse cerebral white matter changes with sparing of the brainstem and cerebellum. The patient was extubated on day 6 and was able to breathe unassisted with minimal oxygen support, but his mental status and neurological exam remained unchanged. His family elected to pursue comfort care measures with placement into a hospice facility where his nasogastric tube feedings were discontinued. He died 23 days after the initial incident.



MRI FLAIR, Day 4

MATERIAL SUBMITTED: H&E section of gray and white matter at the splenium of the corpus callosum.

POINTS FOR DISCUSSION:

1. Diagnosis
2. Pathogenesis