54th ANNUAL DIAGNOSTIC SLIDE SESSION 2013

CASE 2013-8

Submitted by: Caitlin Shannon, Dianne Wilson, Peter Nelson, Melissa Kesler, and Craig Horbinski
Department of Pathology, University of Kentucky Chandler Medical Center, Lexington KY 40536

Clinical History: The patient was a 15 year-old African-American boy with several months of progressively worsening headaches and confusion. He also had at least one seizure. Prior history was significant only for an "eosinophilic cellulitis" requiring systemic steroid therapy at some point in the past (no further details available). Preoperative MRI (below) showed a 5.5 x 3.8 x 3.5 cm extraaxial enhancing mass along the right temporal lobe. Also noted was an enhancing defect of the ipsilateral mastoid bone extending to the scalp (not shown); it was unclear whether the two findings were related.

Four months after undergoing a gross total resection of the mass, followup MRI showed some residual lesion. Eighteen months after surgery, the lesion had regrown a little, but without mass effect or edema (not shown). Up until then seizures were well-controlled with medication, but in the ensuing six months the boy had some breakthrough seizures. No additional changes in the mass were noted as of the most recent imaging, nearly two years after initial resection.

Material submitted: H&E stained slide of the mass and preoperative MRI imaging.
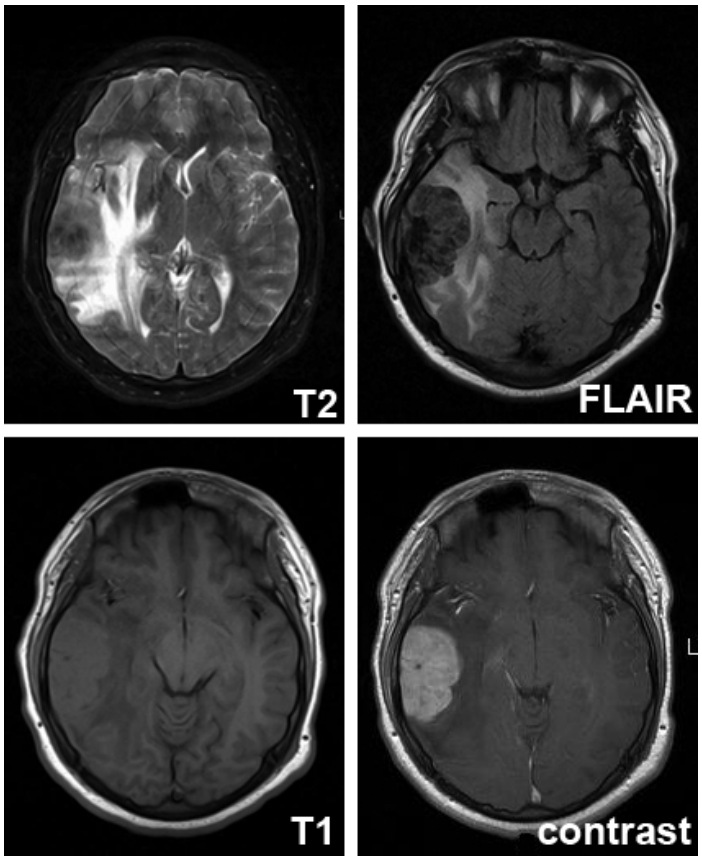
Points for Discussion: Additional stains, differential diagnosis, treatment, prognosis