

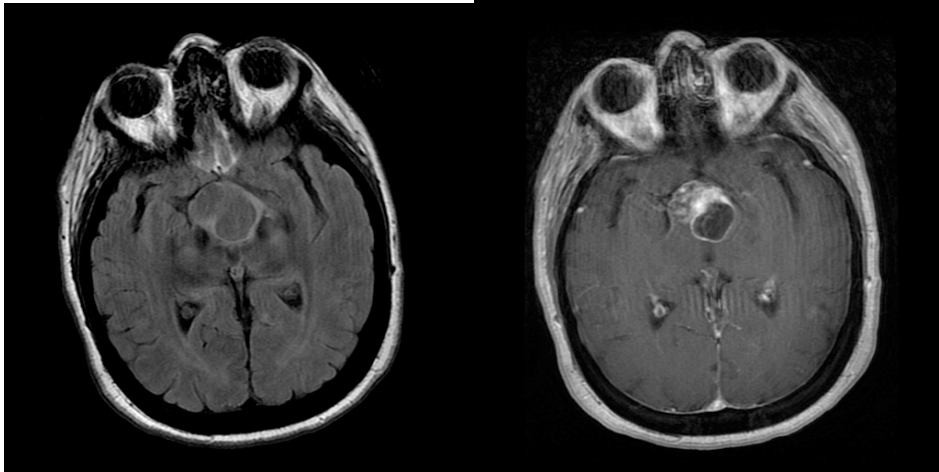
Neuropathology Case

Children's Hospital Friday September 2, 2011

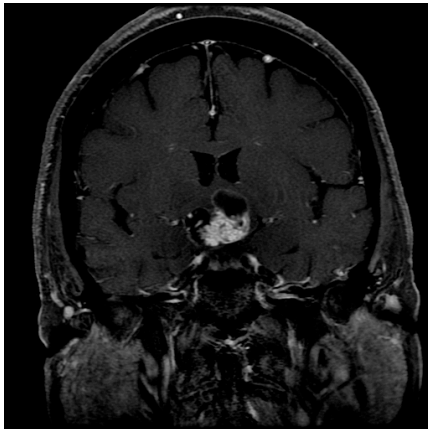
16 year old female with partially cystic, enhancing suprasellar mass.

MRI axial T2 FLAIR

MRI T1 axial +c



MRI T1 coronal +c



[Smear](#)

Diagnosis?

[Permanent H&E](#)

Diagnosis?