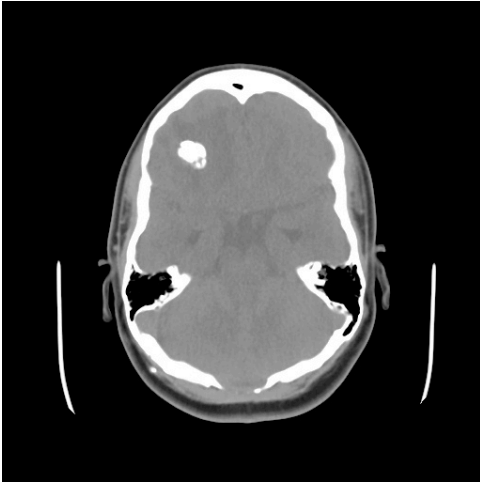


Neuropathology Case

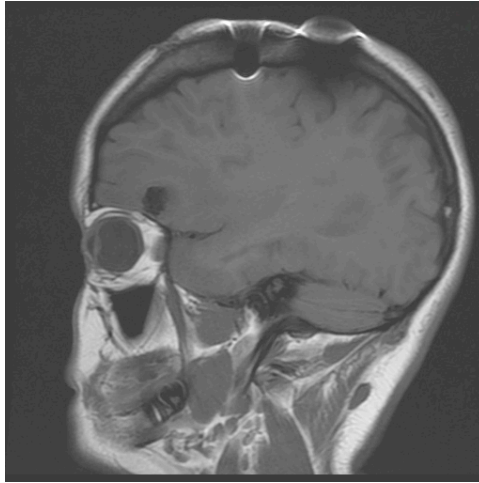
Children's Hospital Conference
Monday, May 23, 2011

20 year old female with h/o Chiari type 2 malformation and VP shunt. Repeated imaging showed slowly developing intracranial lesion. Most recent images see below

CT



MRI



H&E

Diagnosis?