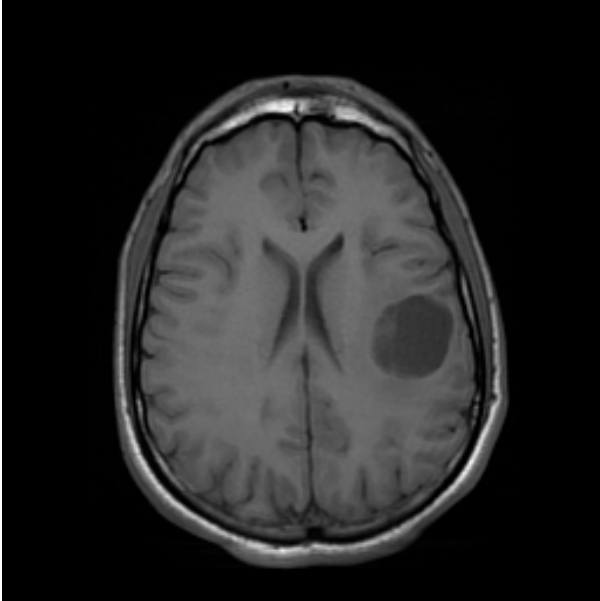


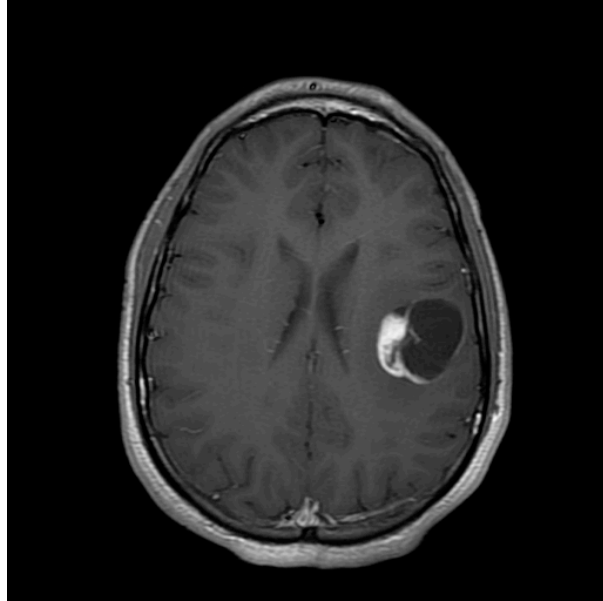
Neuropathology Case
Children's Hospital, Friday, January 6, 2012

17-year old male presenting with seizures

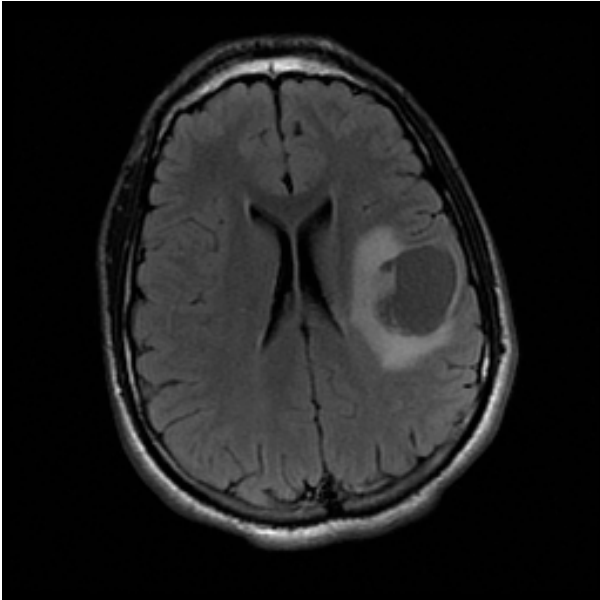
T1 Axial



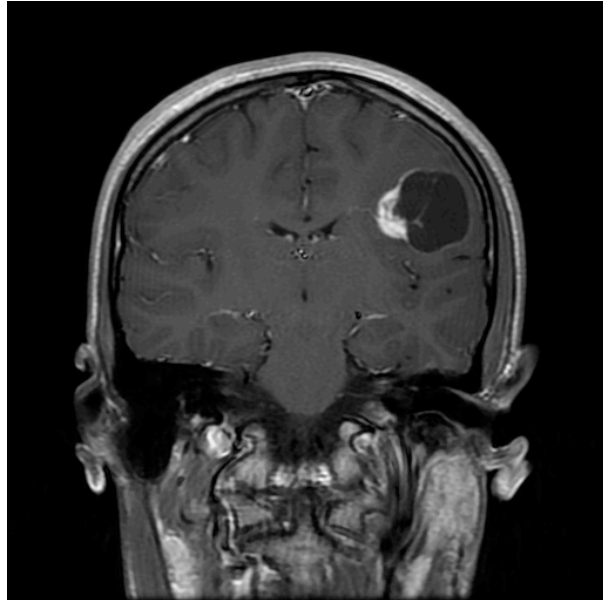
T1 + Contrast



T2 FLAIR



T1 + Contrast



Glass slides: Smear, H&E, GFAP, Ki67

Diagnosis?
Implications for behavior?

FINAL DIAGNOSIS: PILOCYTIC ASTROCYTOMA WITH PILOMYXOID FEATURES