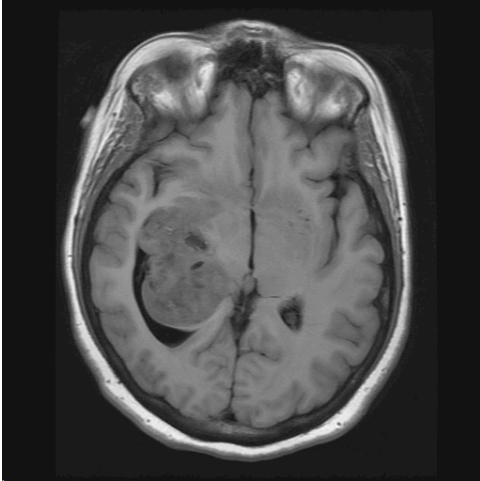


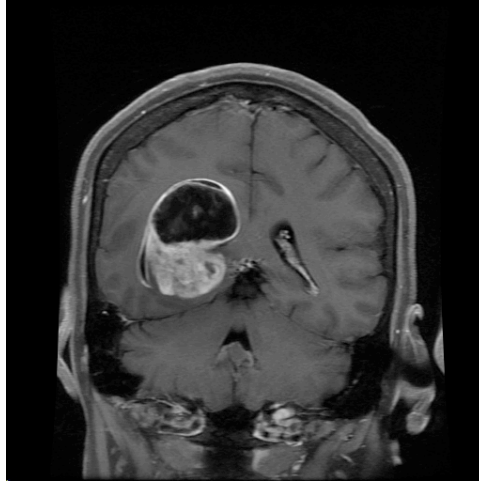
Neuropathology Case

Children's Hospital Conference
Friday January 13, 2011

T1



T1 + contrast



Patient underwent cyst fenestration and tumor biopsy, which was consistent with pilocytic astrocytoma.

Because of recurrent mass symptoms, she underwent partial tumor resection about 6 weeks later:

H&E
Synaptophysin
Ki-67

Diagnosis: Anaplastic ganglioglioma, WHO grade 3

Perilesional

Lesion